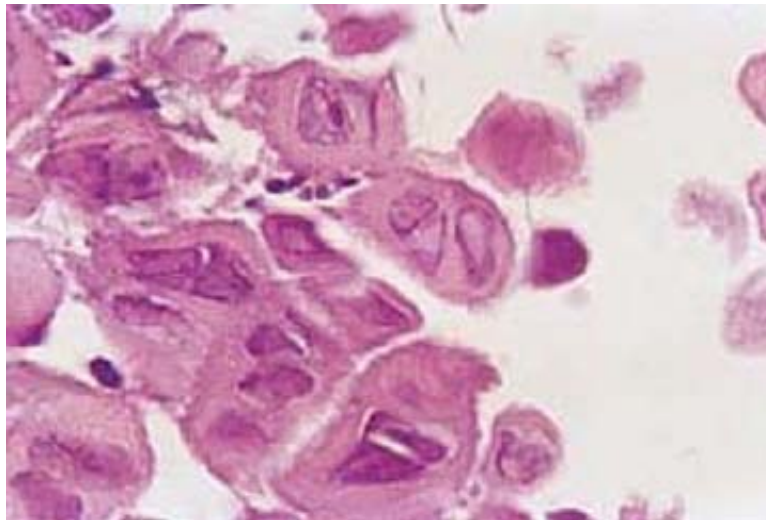
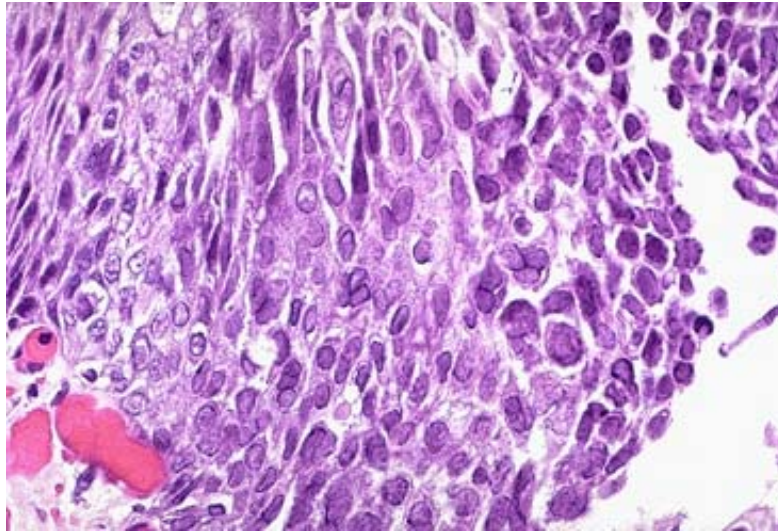


A 47 year-old male s/p recent bone marrow transplantation develops dysphagia and odynophagia. An EGD is performed and you biopsy multiple small, shallow, esophageal ulcerations.

You recommend therapy for what entity?



ANSWER: HSV esophagitis