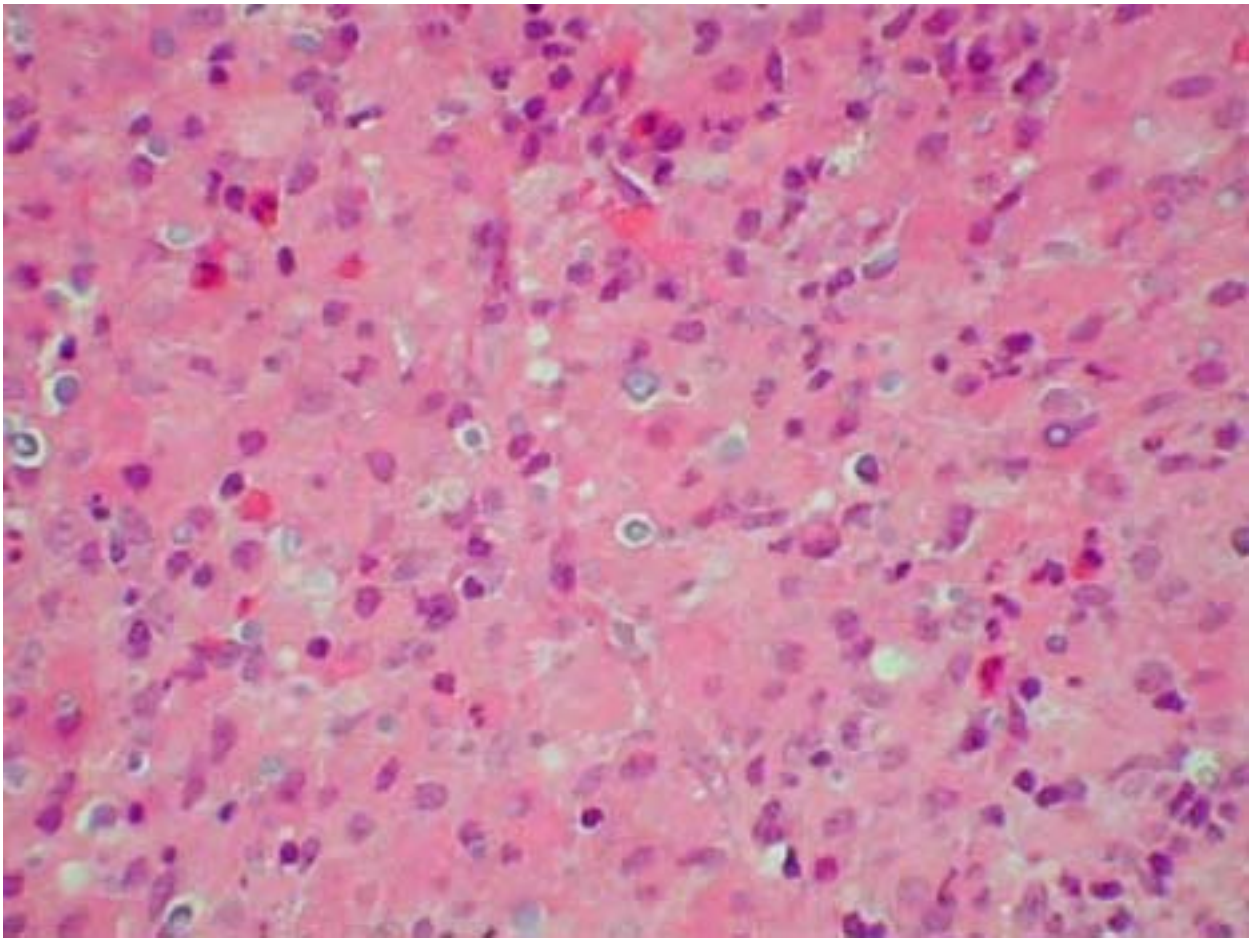


Name this condition of defective macrophage killing resulting in colonic “soft plaques” and chronic granulomatous lesions.



ANSWER: Malakoplakia