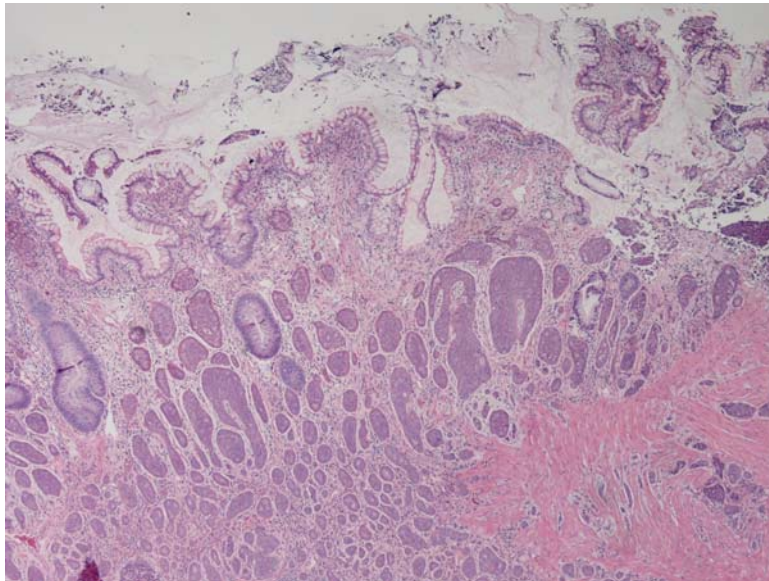
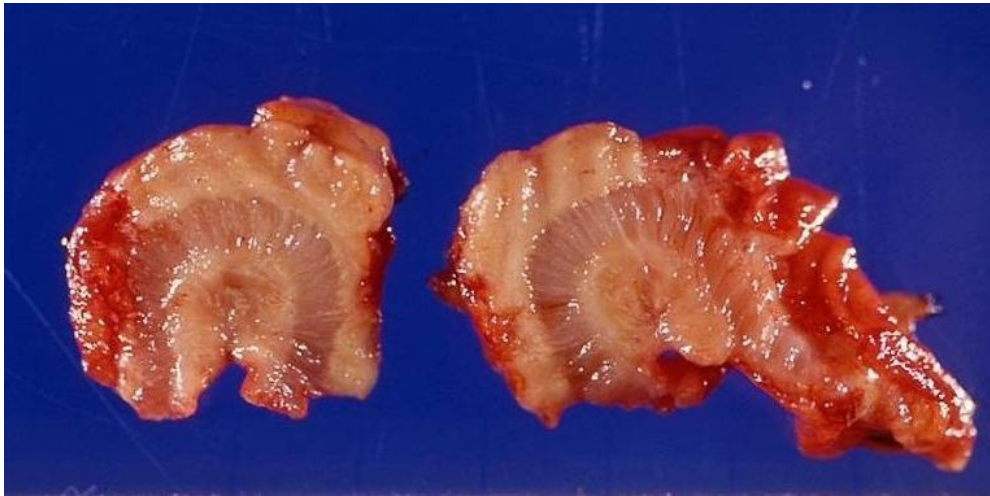


An incidental mass from the appendix is resected, with the gross and histologic findings shown. What is the diagnosis?



ANSWER: The tumor shown is that of an appendiceal carcinoid.

Explanation: On gross specimen, the tumor has a yellowish appearance, and in this case, forms a mucosal and extramural mass, with knuckling of the bowel. Carcinoid tumors are most commonly found in the small intestine (ileum particularly), with the appendix being the second most common site. If located in the appendix, the tumor tends to present earlier than other forms of carcinoid tumors given the luminal obstruction and features of appendicitis, hence the more favorable prognosis given the earlier manifestation of disease. The likelihood of metastatic disease increases with size of the primary tumor, so lesions less than one centimeter require only appendectomy if limited to the appendix, whereas lesions two centimeters or greater are often removed with a right hemicolectomy.