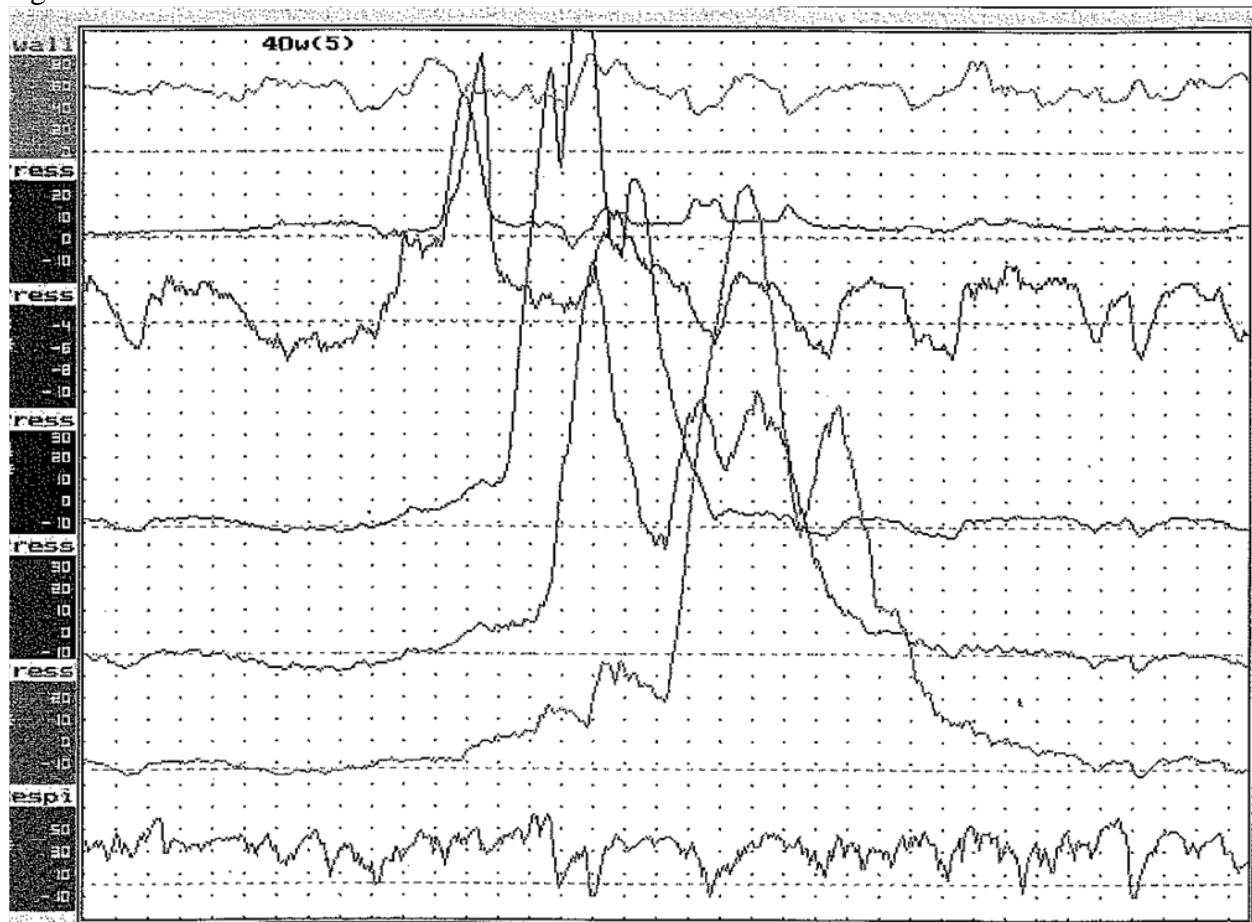


Question 27 – Week of June 11

A 45 year old female with chest pain has an esophageal manometry shown in Figure 1. The most likely diagnosis is:

- A. Achalasia
- B. Vigorous Achalasia
- C. Scleroderma
- D. Nutcracker esophagus
- E. Normal manometry

Figure 1:



Answer: D

Nutcracker esophagus is an esophageal motility disorder characterized by high amplitude peristaltic contractions. Average distal peristaltic contractions often average >180 mmHg.

Reference:

Talley, N. Martin C. Clinical Gastroenterology: A practical problem based approach. 2nd edition: 2006: p.18