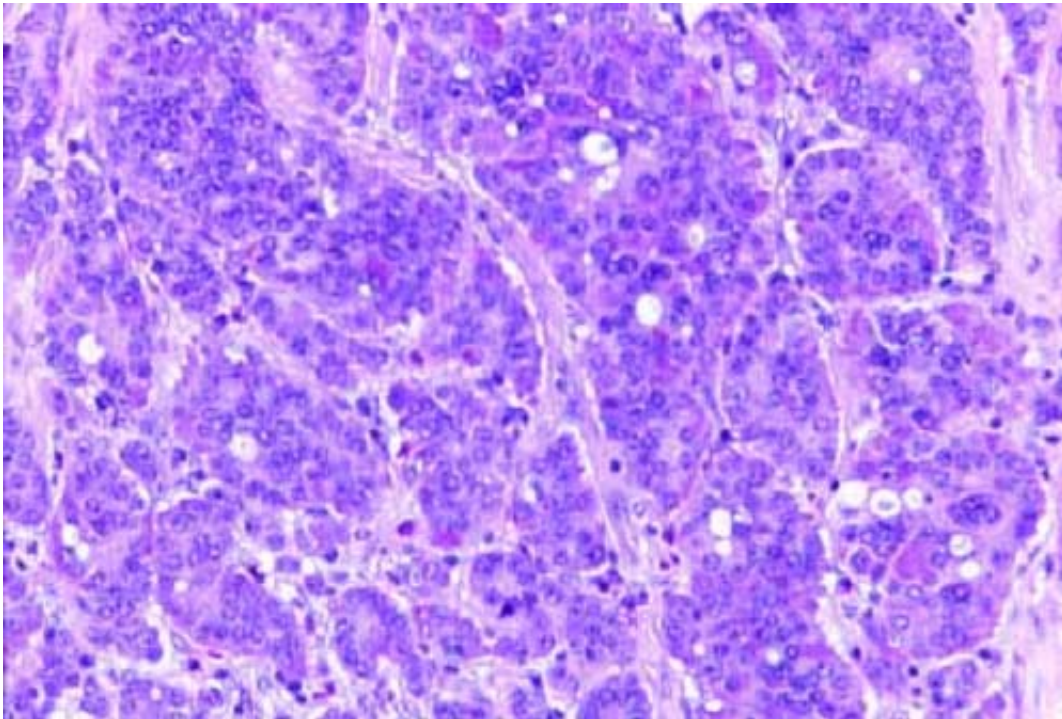


A 55 year-old man has a 2.5 cm submucosal antral mass arising discretely from the submucosa on EUS.

Pathology shows the following, what is the appropriate treatment?



ANSWER: Wide surgical excision is required for foregut carcinoids such as these.