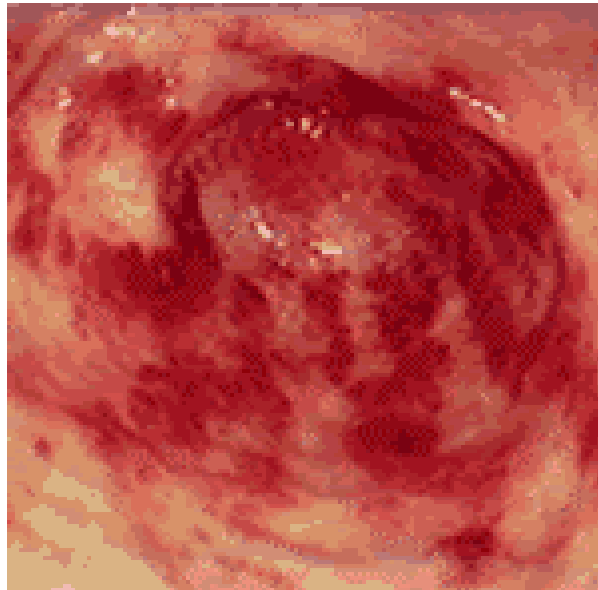


What is the antral lesion in this patient with iron deficiency anemia?



**ANSWER: Gastric antral vascular ectasia / GAVE / Watermelon stomach; The most common clinical profile of the patient with watermelon stomach is an elderly (>70 years-old) female with severe iron deficiency anemia, slow GI blood loss, and no history of cirrhosis.**