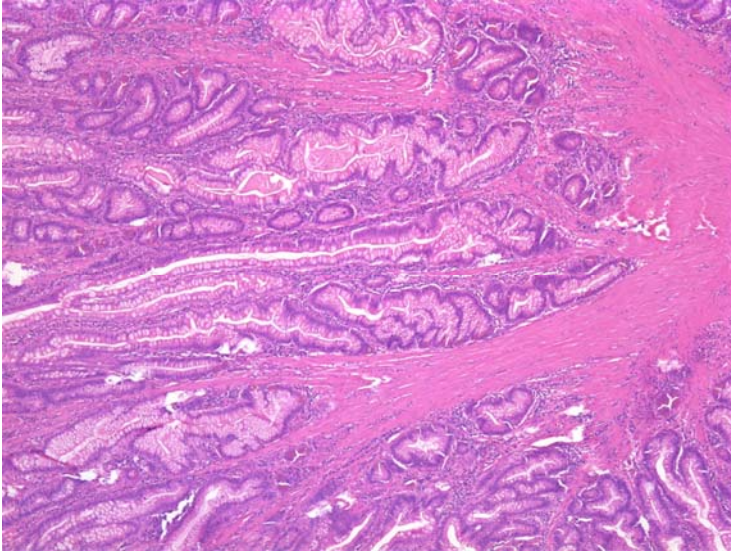


A 32 year old female was admitted with abdominal pain and was found to have evidence of intussusception on imaging. She was brought to the operating room where a short segment of small bowel was removed containing multiple polyps as seen here. She has other family members with this condition as well.



This patient is at increased risk of all of the following malignancies EXCEPT:

- a. Breast
- b. Pancreatic
- c. Thyroid
- d. Colon
- e. Esophageal

ANSWER: C

The polyp shown is typical of a Peutz-Jeghers polyp, which are hamartomatous with a prominent smooth muscle infrastructure in the lamina propria. Patients with this autosomal dominant condition are at increased risk of breast, pancreatic, colon, esophageal, ovarian sex cord and Sertoli testicular tumors. There is no increased risk of thyroid cancer as one may see in FAP, where an adenomatous polyp rather than hamartomatous polyp would have been seen.