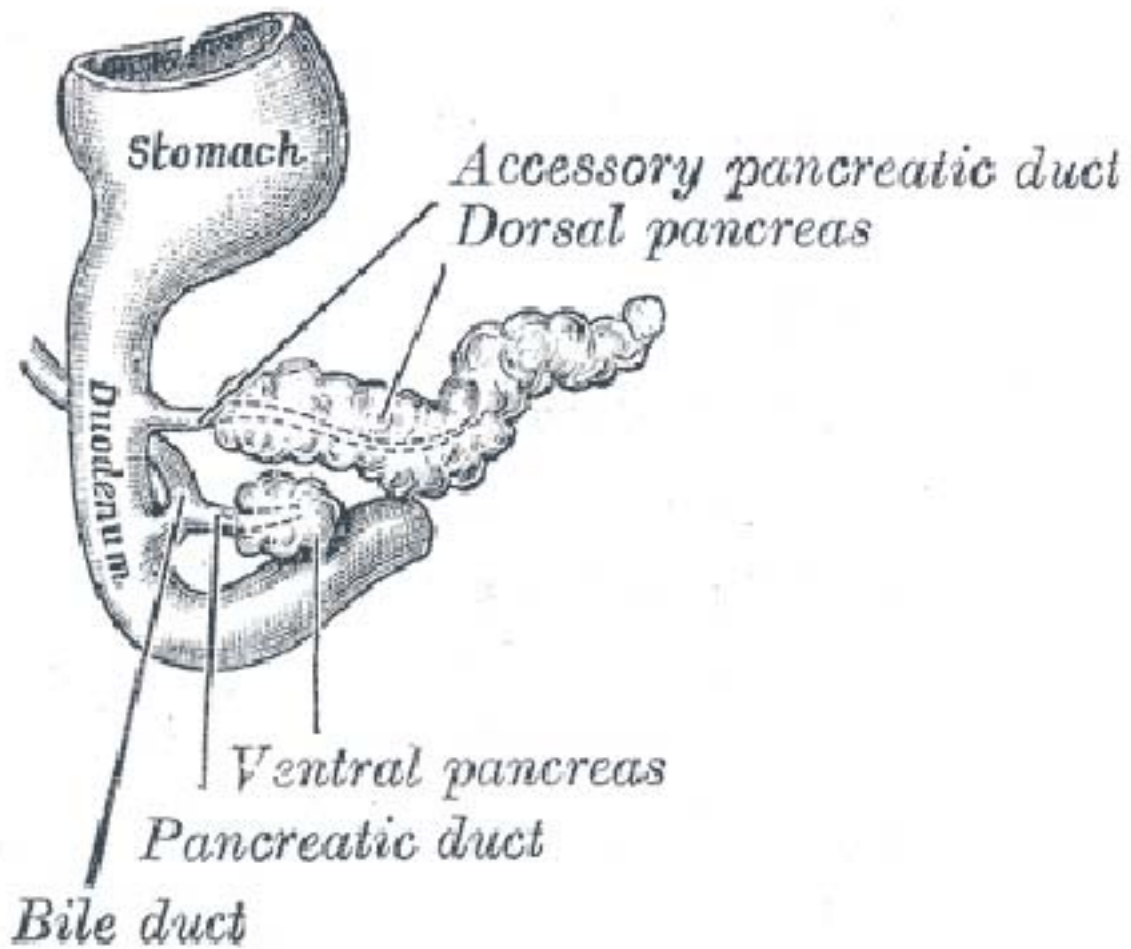


This embryologic illustration from Gray's Anatomy shows the unfused pancreatic ducts.

Which ductal structure is also known as the duct of Santorini?



ANSWER: Accessory pancreatic duct