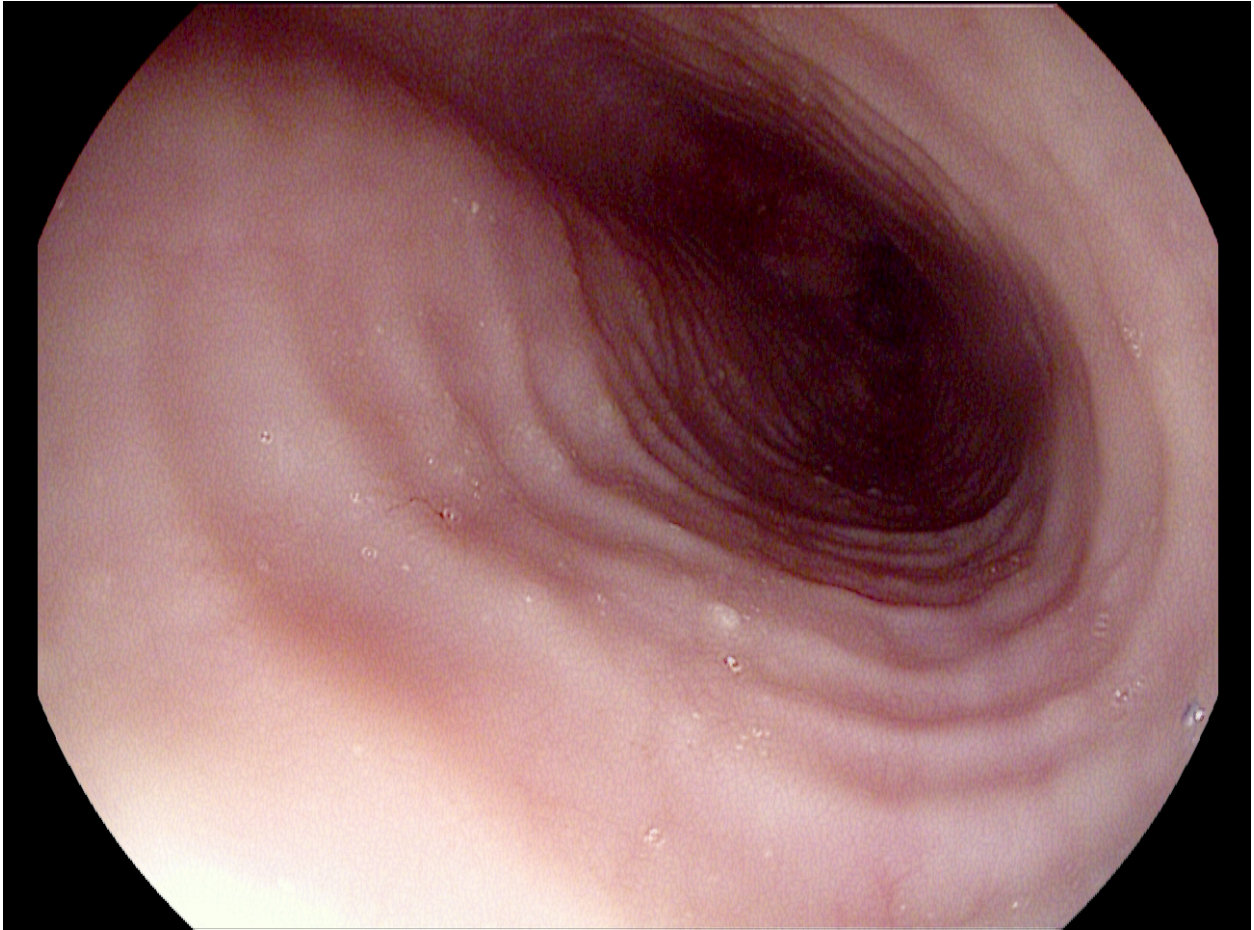


Question 45 – June 15

25 year old male with history of dysphagia to solid foods presents with acute food impaction. His past medical history is positive only for asthma. The endoscopic image after the food bolus clearance is shown.



The patient was found to have isolated esophageal mucosal eosinophilia with > 20 eosinophils per high power field on biopsy. The most appropriate initial pharmacologic treatment according to the 2013 ACG guideline is:

- A. PPI therapy
- B. Topical steroids
- C. Prednisone
- D. Montelukast

Answer: A

Reference:

ACG Clinical Guideline: Am J Gastroenterol 2013; 108:679–692.