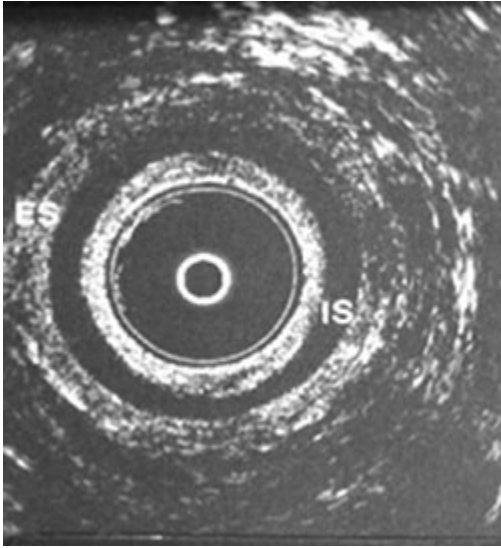


Question 1 – Week of February 18

A 40-year-old woman, gravida 1, presents with 2 year history of intermittent fecal incontinence. How would you interpret her anal endosonography shown in the figure?



- A. External anal sphincter defect
- B. Internal anal sphincter defect
- C. Anterior defect of external and internal anal sphincter
- D. Posterior defect of internal anal sphincter
- E. Normal exam

Answer: E

Anal endosonography is a useful test for defining anal sphincter morphology. It is a simple, inexpensive and widely available test but is not infallible. In this particular example, the dark halo, which is semilunar in shape, is the internal anal sphincter which appears intact. Just adjacent to the internal anal sphincter, the white more sonoresistant area depicts the external anal sphincter. The external anal sphincter is also intact. Thus, this patient has intact external and internal anal sphincter muscles.

References:

1. Rao SSC, Patel R. How useful are manometric tests of anorectal function in the management of defecation disorders? *Am J Gastroenterol* 1997;92:469-75.
2. Rao SSC. Diagnosis and management of fecal incontinence. *Am J Gastroenterol* 2004;99:1585-1604.
3. Diamant NE, Kamm MA, Wald A, Whitehead WE. AGA technical review on anorectal testing techniques. *Gastroenterology* 1999;116:735-60.