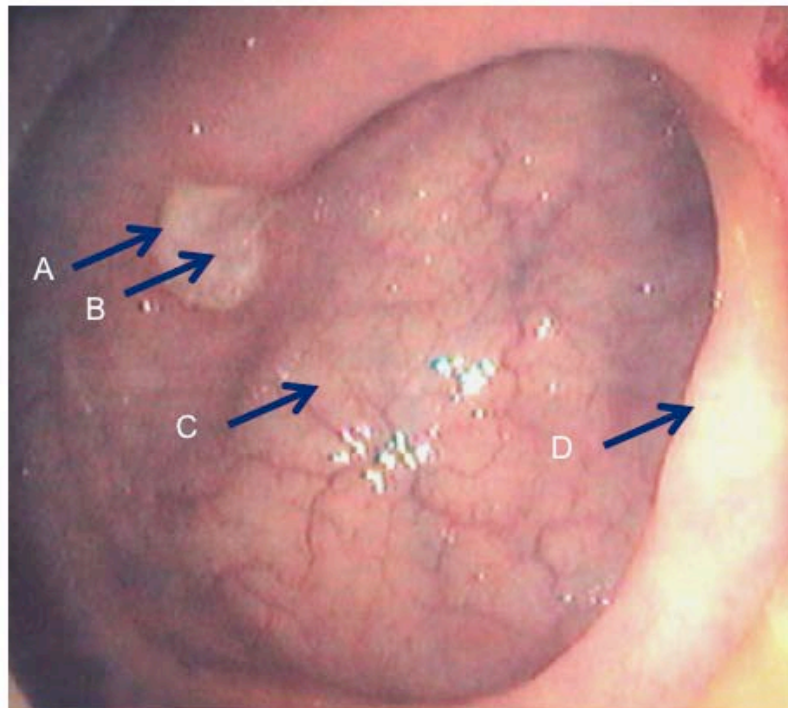


### Question 41 – Week of May 20

A 23 year-old male with UC previously well controlled on 4.8 g mesalamine a day presented with increased urgency, bloody diarrhea, fevers for one week. He was admitted to the hospital and was treated with IV steroids. After 5 days his symptoms did not improve, and in fact had worsened with more bowel movements a day and more blood in her stools. A colonoscopy was performed and showed ulcers such as the one below. What is the best place to take a biopsy sample to make the diagnosis?



### Answer: B

The case describes a case of CMV complicating UC, presenting as steroid-refractory UC. When ulcers are found on biopsy, the center of the ulcer is the best place to take a biopsy (compared to HSV – the best place to diagnose HSV is at the edge of the biopsy). When CMV ulcers are suspected, histology and immunohistochemistry are the best test to make the diagnosis.

### References:

Galiatsatos P, et al. Meta-analysis of outcome of cytomegalovirus colitis in immunocompetent hosts. *Dig Dis Sciences*. 2005. 50(4): 609-16.

Kandiel A et al. Cytomegalovirus colitis complicating inflammatory bowel disease. *Am J Gastro*. 2006. 101: 2856-65.