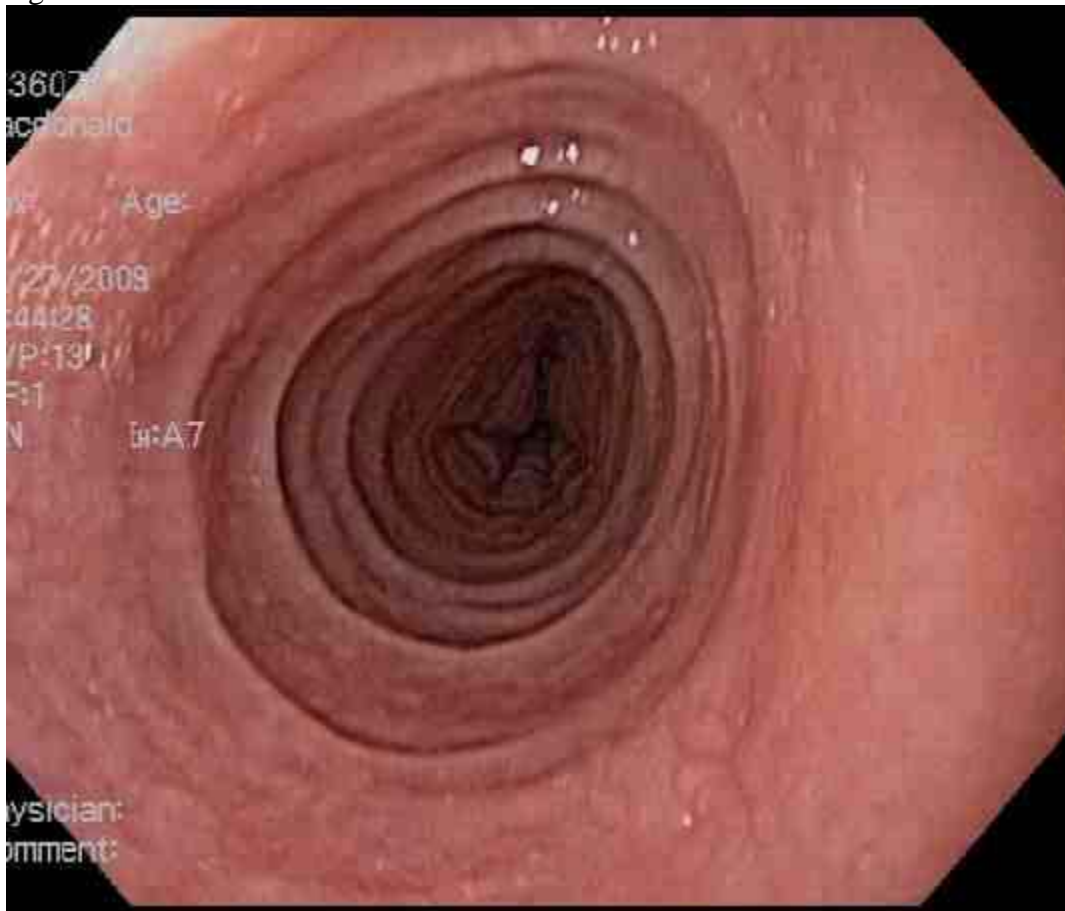


Question 12 – Week of February 27

A 19 yr old female with no medical history presents for a history of intermittent dysphagia and a recent visit to the emergency room for a food impaction. On EGD the following appearance of the esophagus is noted. Biopsies of the esophagus are likely to yield which of the following?

- A. Intestinal metaplasia
- B. Active esophagitis with mucosal disruption
- C. A dense lymphocytic infiltrate
- D. Eosinophilic infiltration

Figure 1:



Answer: D

The history and endoscopic image are typical for eosinophilic esophagitis. These patients often present with dysphagia. EGD classically shows the typical ringed appearance, sometimes referred to as feline esophagus.

Reference:

Sleisenger and Fordtran's Gastrointestinal and Liver Disease. 9th edition. 2010. Chapter 27