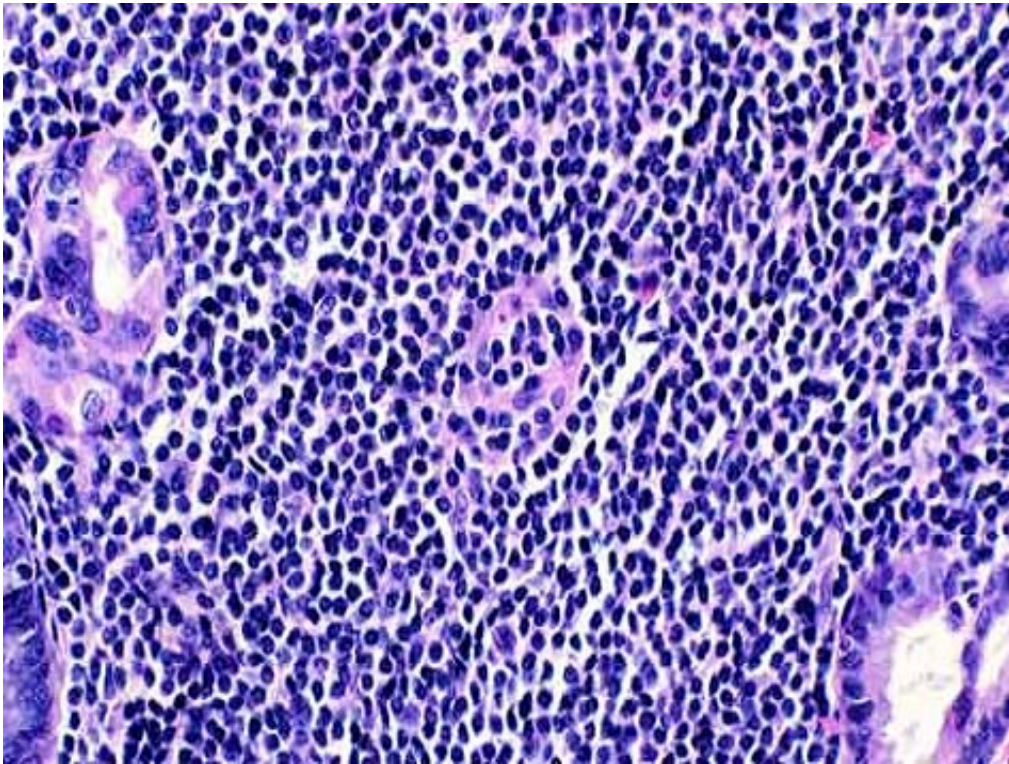


A 39 year-old female with a history of NSAID use, vitiligo, and ovarian cancer presents for epigastric pain. An EGD shows a 2 X 2 cm ulcer with two smaller satellite ulcers.

Biopsy shows the following, what is the diagnosis?



ANSWER: MALT lymphoma