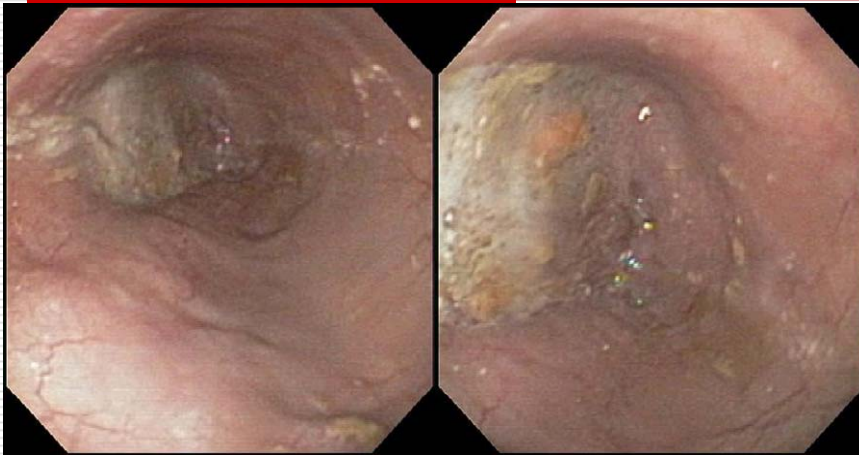


This endophoto of the esophagus could be consistent with the following symptoms or diagnosis:

EGD



- a. Dysphagia
- b. Pulmonary fibrosis
- c. Squamous cell carcinoma
- d. All of the above

ANSWER: D

This is a case of achalasia.