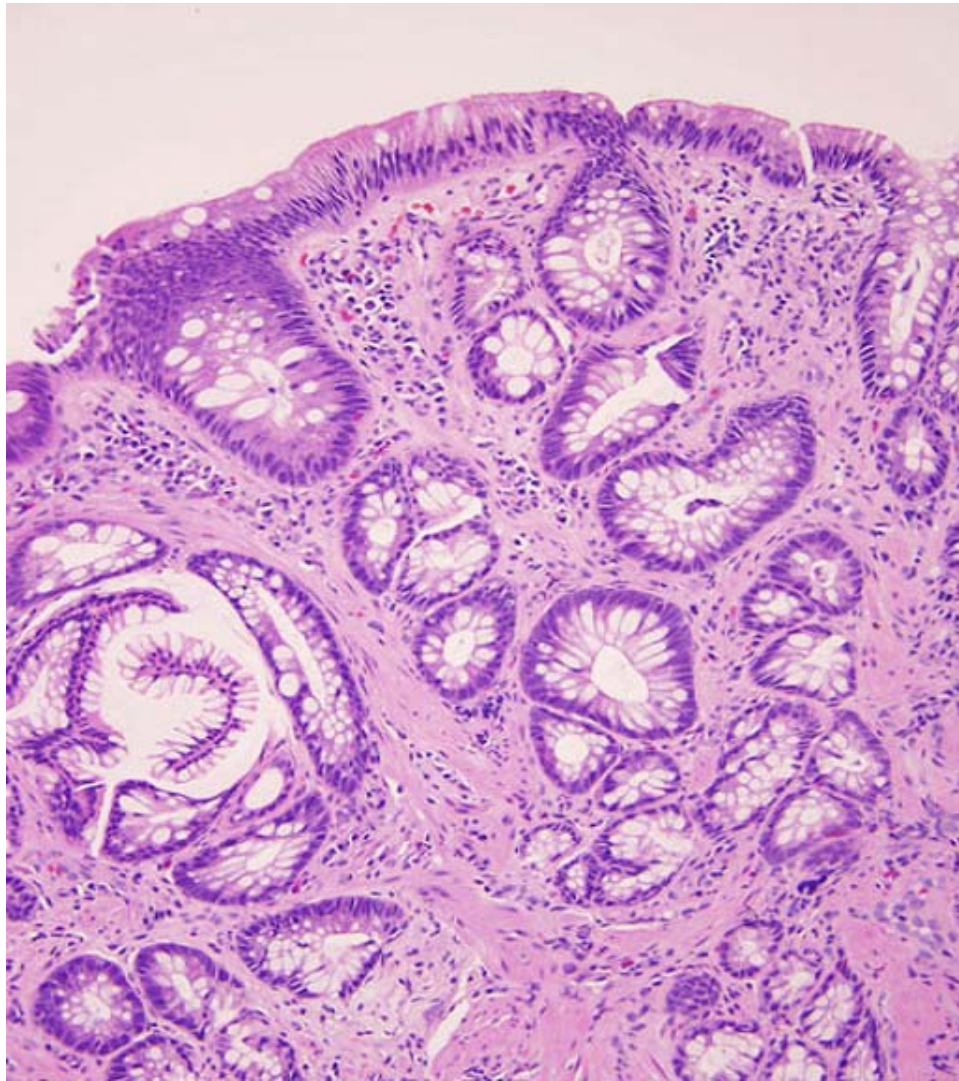


A 52 year-old female with multiple sclerosis and long term history of constipation is found to have a 4 mm rectal polyp on colonoscopy.

What is the diagnosis?



ANSWER: Solitary rectal ulcer syndrome