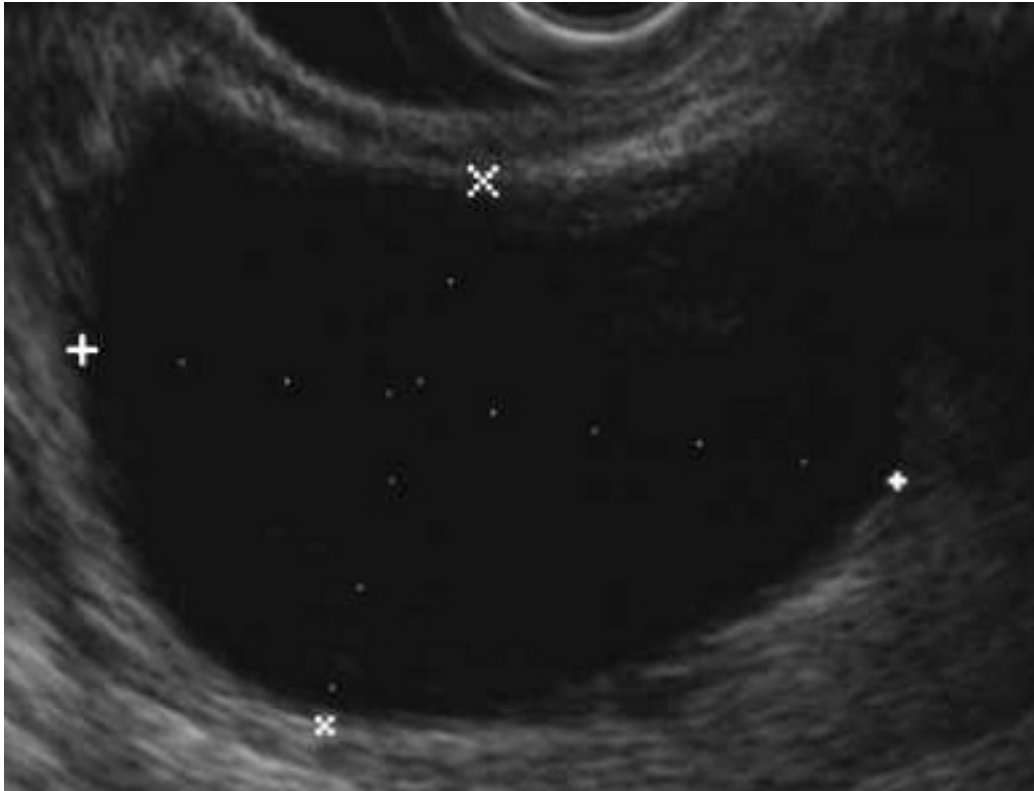


A 53 year-old woman with no symptoms is incidentally found to have a single cystic lesion in the body of the pancreas. EUS with FNA is positive for Mucin staining. You recommend what therapy?



ANSWER: Surgical removal of mucinous cysts is recommended because of the malignant potential.

JOP. J Pancreas 2004; 5(4):289-303.

Defining the Diagnostic Algorithm in Pancreatic Cancer

John David Horwhat, Frank G Gress

**Division of Gastroenterology, Department of Medicine, Duke University Medical Center.
Durham, North Carolina, USA**

Algorithm for pancreatic lesions (cystic lesions).