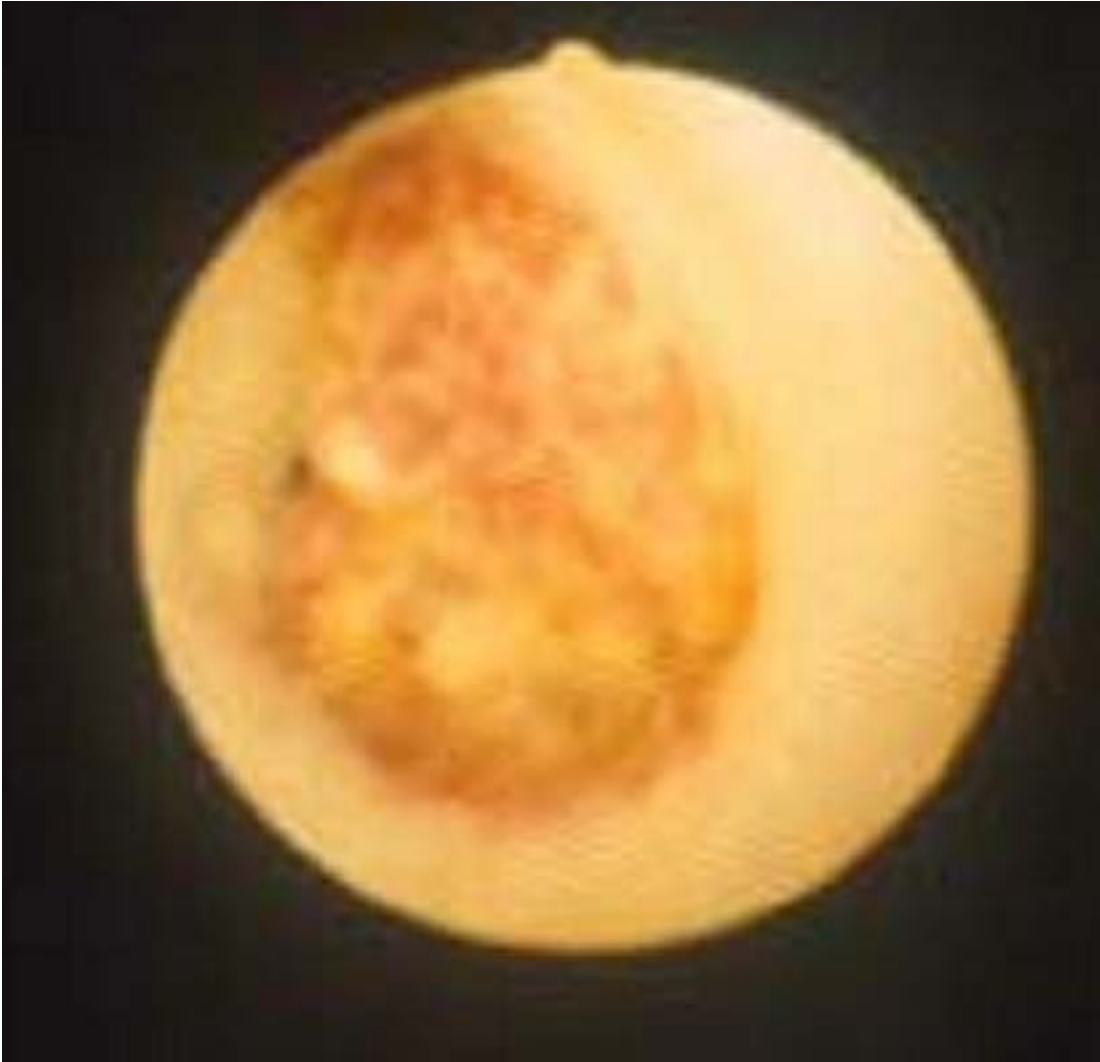


What does this Choledochoscopy show is the cause of this patient's obstruction?



ANSWER: Cholangiocarcinoma