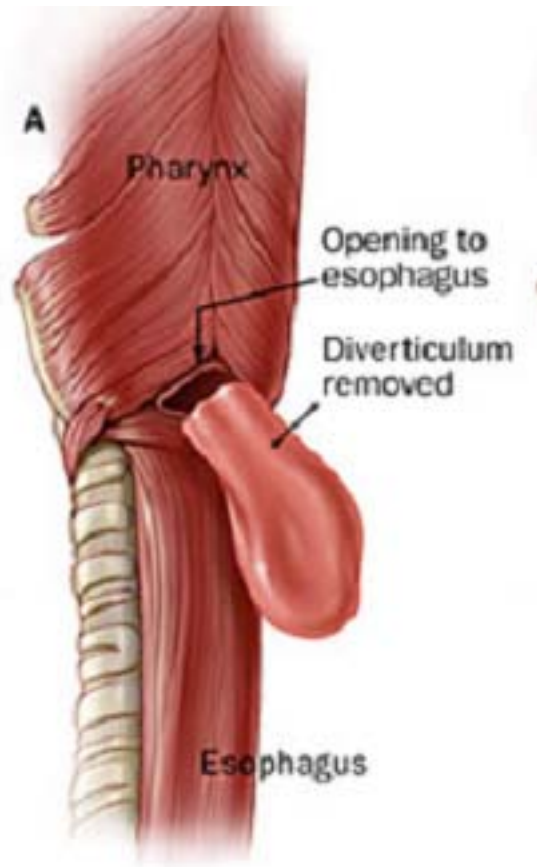


This anatomic triangle is bordered by the inferior pharyngeal constrictor superiorly and the cricopharyngeus muscle inferiorly, and is the most common site of weakness resulting in a Zenker's diverticulum.

Name it.



**ANSWER: Killian's triangle**