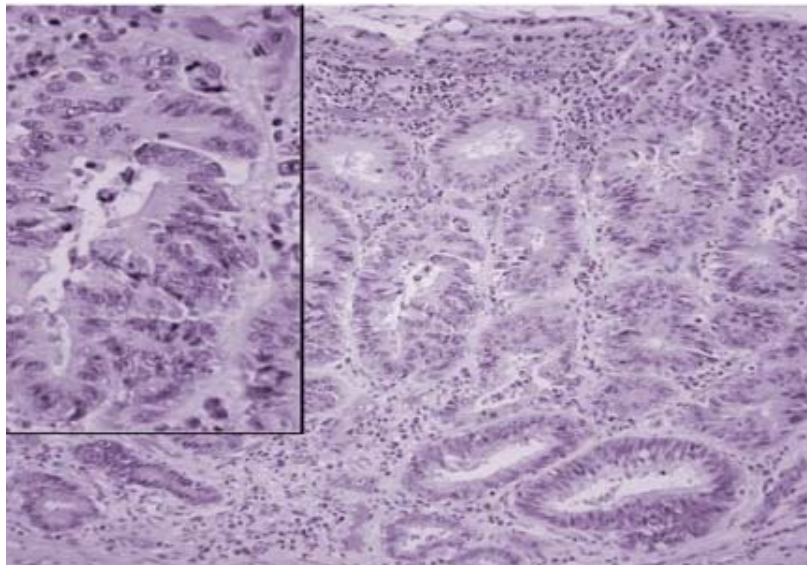
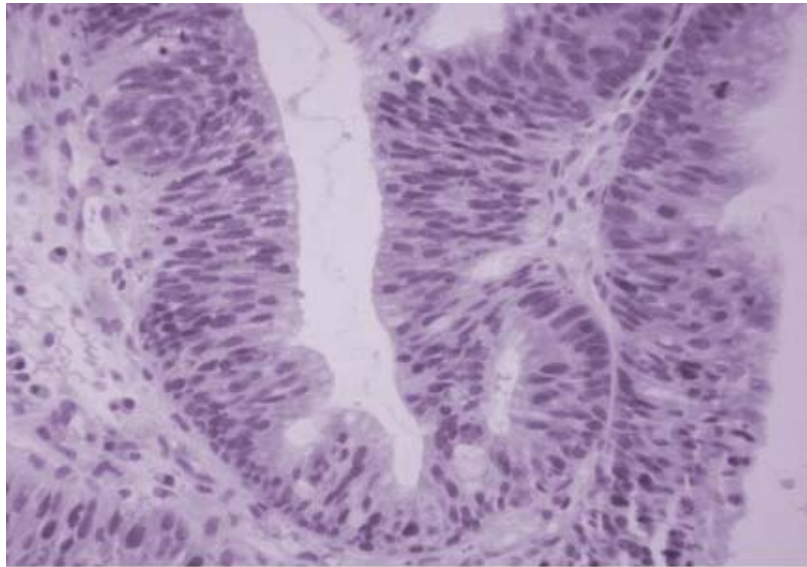


A 38 year-old male with a 12 year history of pan-colonic ulcerative colitis has biopsies of normal appearing flat mucosa.

What therapy do you recommend?



**ANSWER: Total colectomy**

**Explanation: When diffuse dysplasia is seen in the face of chronic inflammation from UC, the risk of cancer is high and colonic resection is both curative and preventative.**