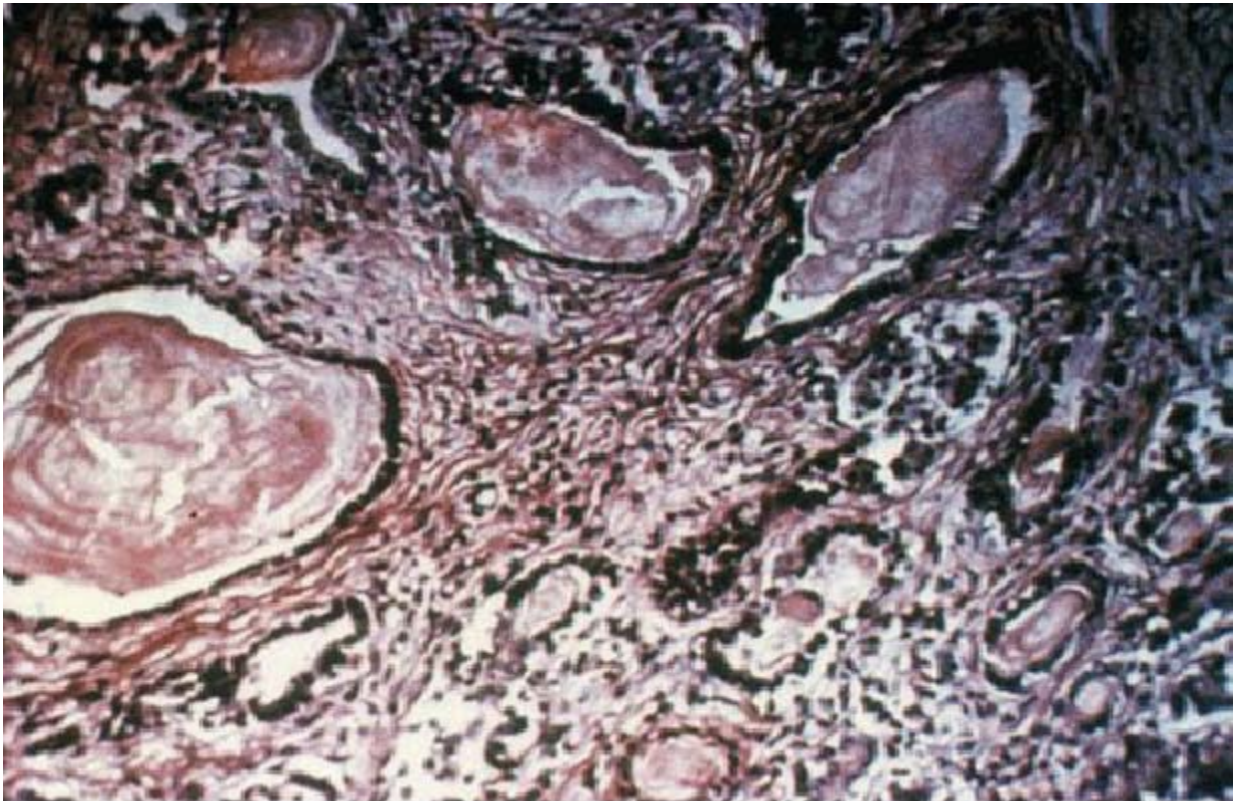


This pancreatic biopsy is from an 18 year-old man with variceal bleeding and pancreatic insufficiency.

What is his diagnosis?



**ANSWER: Cystic fibrosis**

**Explanation: Inspissations of bile cause plugging, which leads to hepatic dysfunction and fibrosis.**