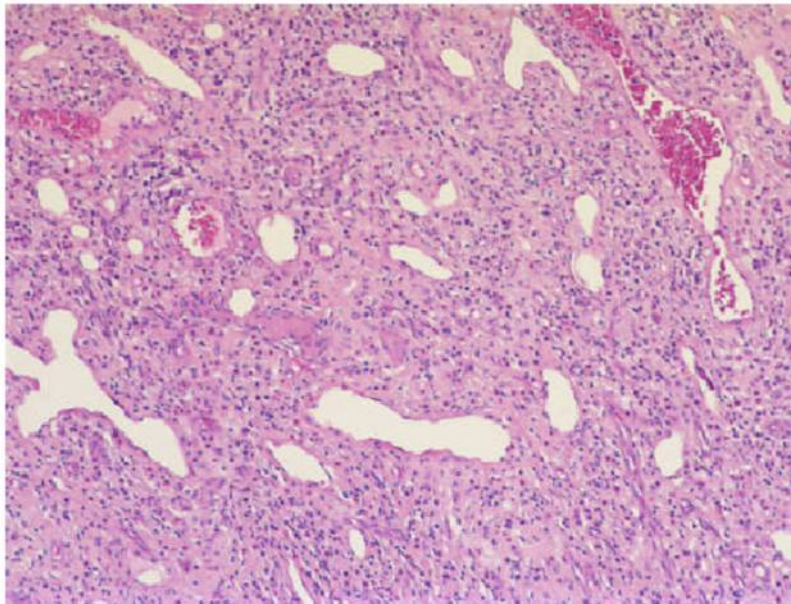
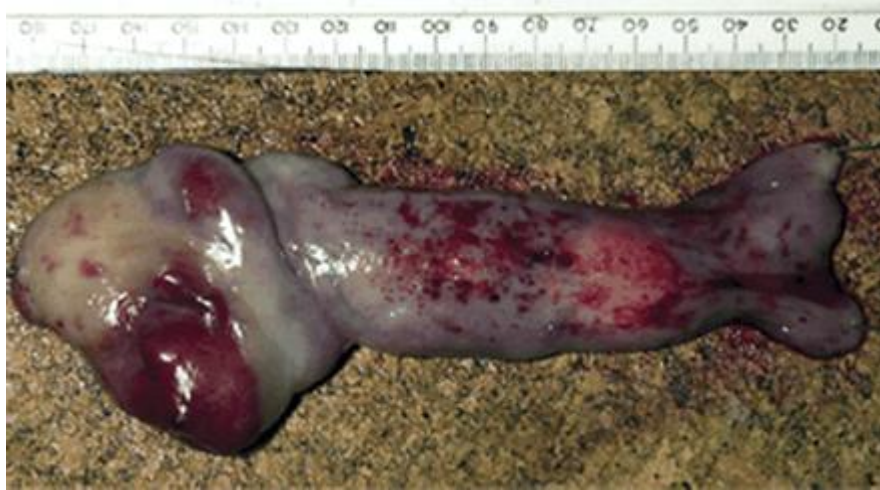

A patient regurgitates a fleshy mass into the mouth. It is biopsied and resected.

What is the most probable diagnosis?



ANSWER: Fibrovascular polyp