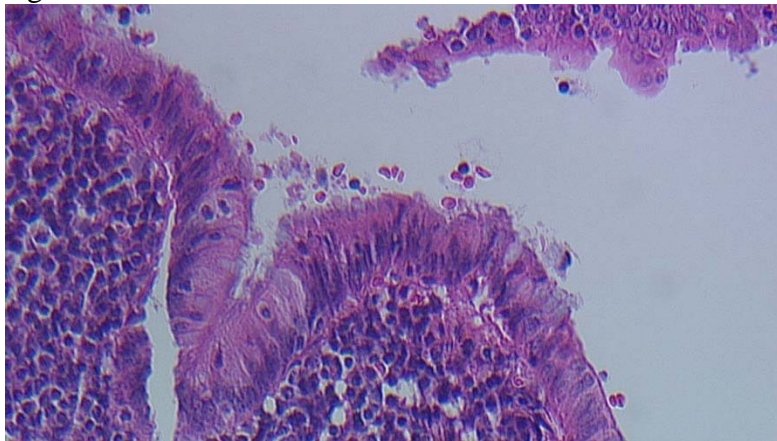


Question 3 – Week of August 20

51 year old man with HIV complains of chronic watery diarrhea, weight loss and vague abdominal pain. Patient had a colonoscopy with biopsies. The histology from the proximal colon is shown below in Figure 1 and 2. What is the diagnosis?

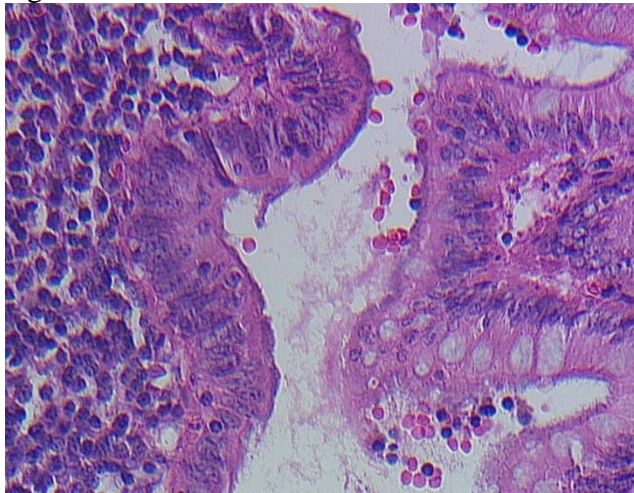
- A. Spirochetosis
- B. Giardiasis
- C. Amebiasis
- D. Cryptosporidiosis
- E. Candidiasis

Figure 1:



(Courtesy of Julian Perez, MD Gastroenterology department, Ronald Miick, MD Pathology department. Albert Einstein Medical Center, Philadelphia)

Figure 2:



(Courtesy of Julian Perez, MD Gastroenterology department, Ronald Miick, MD Pathology department. Albert Einstein Medical Center, Philadelphia)

Answer: A

Written explanation of answer: Human intestinal spirochetosis is a condition defined histologically by the presence of spirochetal microorganisms attached to the apical cell membrane of the colorectal epithelium. Homosexuals and HIV-infected individuals are at high risk of being colonized. Of unknown reason, homosexual and HIV-positive men as well as children are more likely to be symptomatic irrespective of invasion.

Reference:

Tsinganou E, Gebbers JO Human intestinal spirochetosis--a review. Ger Med Sci 2010