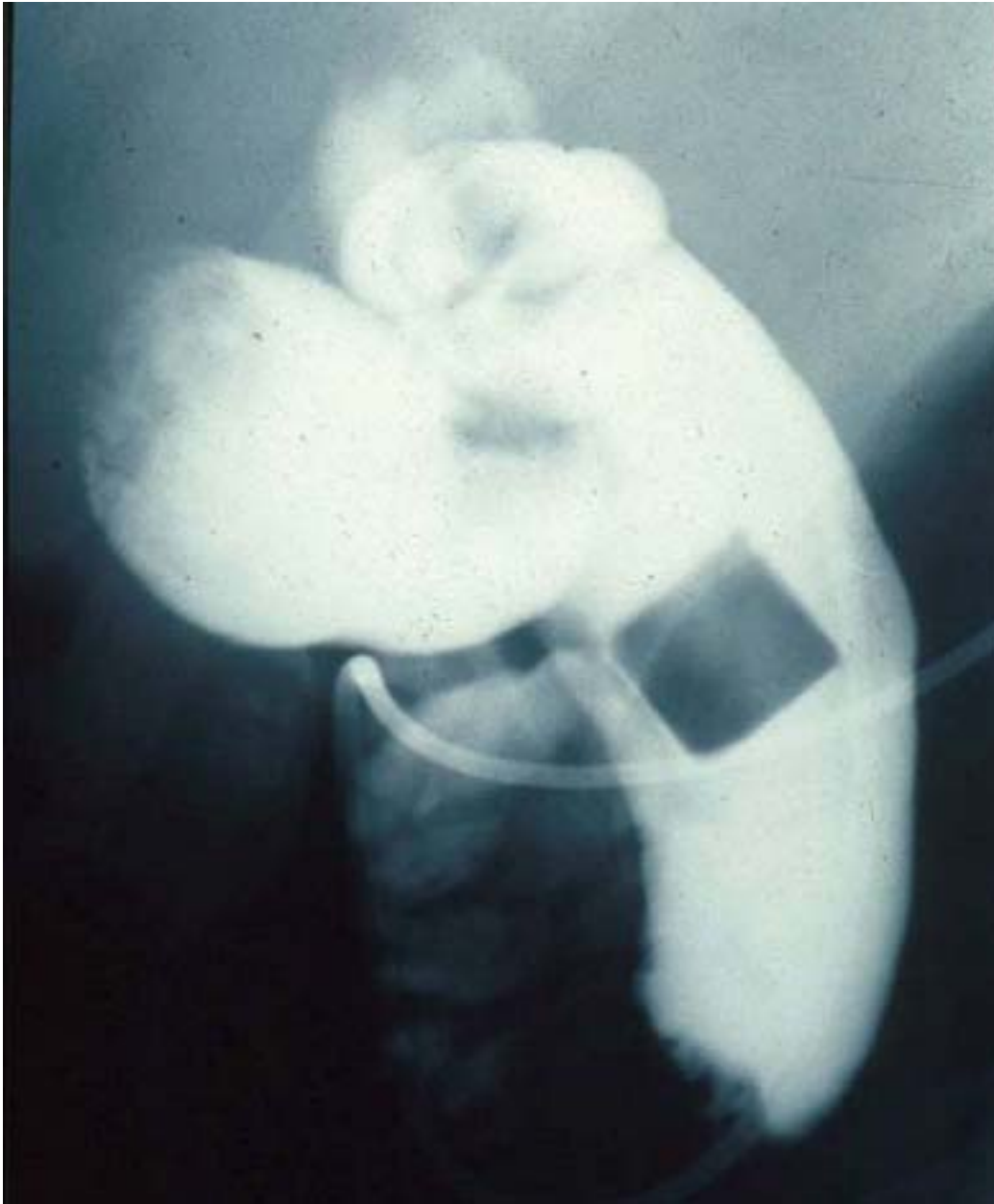


This Cholangiogram shows a large filling defect.

How was this study obtained?



ANSWER: Via Nasobiliary Drain. A nasobiliary drain can be placed at the time of ERCP to allow access for the administration of medicines, dissolution agents and for cholangiograms.